

ARTHROSCOPIC ASSISTED PROXIMAL
HAMSTRINGS REPAIR WITH HUMAN
ACELLULAR DERMAL ALLOGRAFT PATCH
AUGMENTATION FOR REVISION OF FAILED
PROXIMAL HAMSTRINGS REPAIR:
SHORT TERM CLINICAL AND MRI RESULT

John J Christoforetti, MD
Pittsburgh, Pennsylvania



JOHN J CHRISTOFORETTI, MD

I have financial relationships with the following companies:

Consulting: Arthrex, Inc. Breg, Inc

Royalties: Arthrex, Inc.

INTRODUCTION

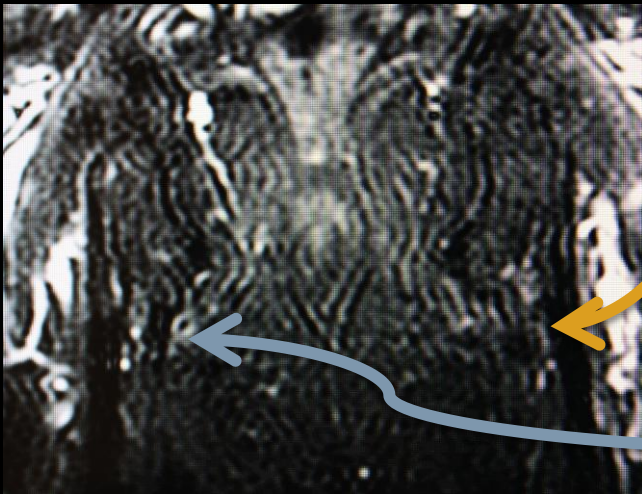
- Proximal hamstrings injury is recognized as an increasingly common clinical entity^{3,4}
- Senior athletes present unique challenges to healing of conservative and surgical treatments for this injury and consequences of loss of mobility are higher in this group
- Conservative management has been suggested for treatment of partial thickness tears and tears with minimal retraction³
- Upon failure of conservative management, surgical treatment has shown promising results^{2,3,4}
- Little evidence is available to guide treatment of failed surgical management of proximal hamstrings injuries in particular for elderly patients

HYPOTHESIS

- Atraumatic re-rupture of proximal hamstrings repairs involves biological and mechanical failure mechanisms
- Biological failure occurs when tendon to bone healing fails OR upon intratendinous separation from an intact repair site
- Mechanical failure occurs with suture anchor, suture-suture, or screw-tendon-bone construct pull out or loss of integrity prior to healing
- Revision reconstruction requires surgical intervention addressing both modes of failure as determined by recurrent pathology

HISTORY

- Patient is an 83 year old male active in cycling, hiking, tennis, sailing and fitness exercise who presented after several weeks of lateral hip pain. An MRI was obtained to investigate for occult hip fracture providing opportunity for pre-injury view of the hamstrings origin (below).

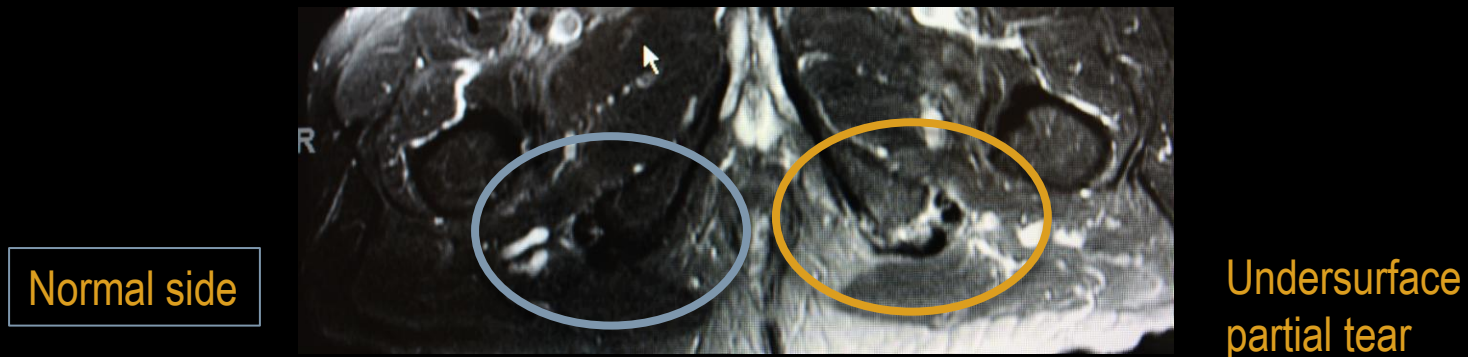


Coronal T2 demonstrates intact origin
Degenerative tendinopathy at medial insertion
For **pre-injury** side

Versus normal side

ACUTE INJURY: ECCENTRIC CONTRACTION

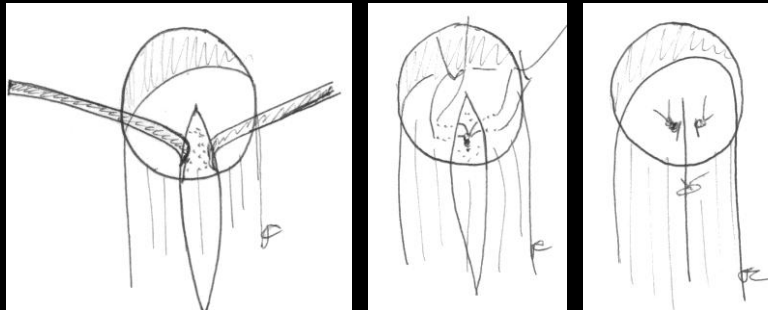
- The patient reported two months later after acute onset of ischial tuberosity pain without back pain or sciatica after stepping over a fence. He described feeling “kicked” in the buttock. Ambulation and sitting were painful and he was forced to use an assistive device.
- Examination findings significant for tenderness at ischial hamstrings origin, no muscular contour abnormality or bruising, and normal neurovascular exam despite pain mediated weakness in prone knee flexion. Conservative management was initiated for presumed **partial injury** and MRI obtained as below.



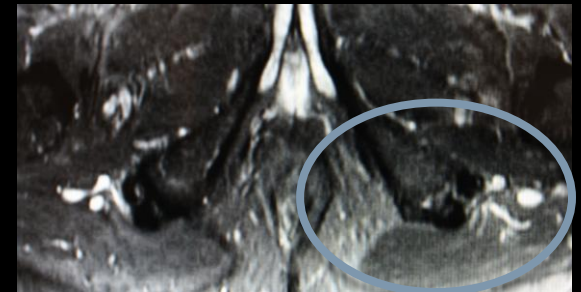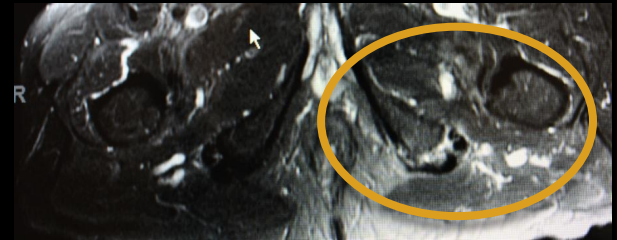
INDEX PROCEDURE:

OPEN REPAIR WITHOUT TAKEDOWN OF NORMAL TENDON

- 4 months conservative care attempted and failed with continued sitting and walking pain
- Initial surgical approach was via a gluteal fold incision with preservation of gluteus maximus insertion as described by Cohen *et al*³
- Repair site was secured with a single 3.0 bioabsorbable anchor by dividing superficial origin fibers longitudinally, preparing host bone at partial tear site, and securing tendon
- Immediate postoperative period complicated by urinary retention requiring urethral catheter insertion and delayed removal by urology
- Complete symptom resolution enjoyed by 2 weeks postoperative status



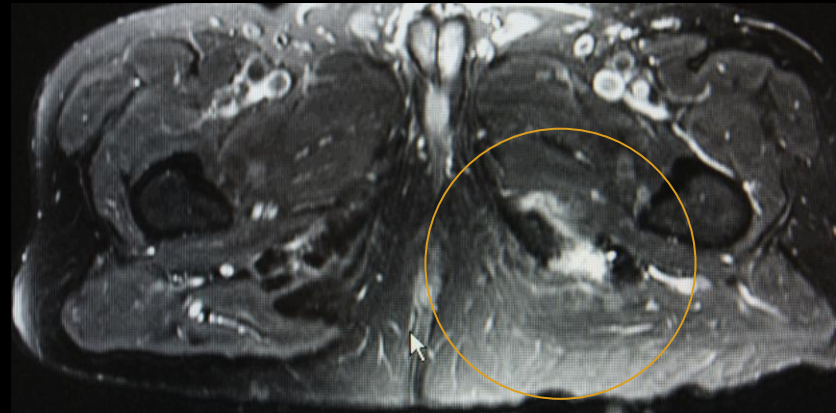
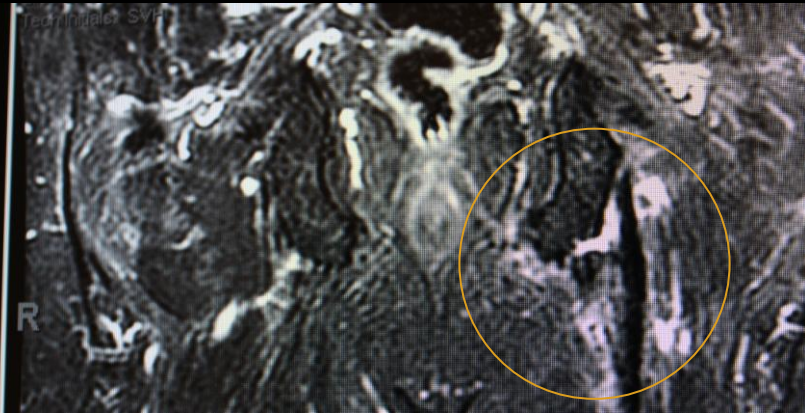
Injury (partial tear)



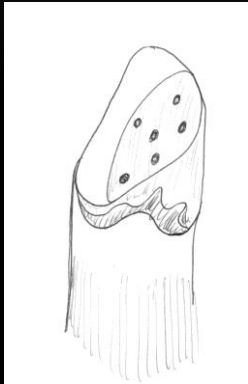
Post Repair Image (6 wks)

REINJURY: RECURRENT TEAR WITH FAILURE AT SUTURE TENDON JUNCTURE (BIOLOGIC FAILURE?)

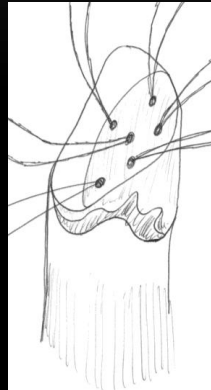
- Patient returns to office at 8 weeks postoperative status after rapid forward lean caused acute return of pain and disability.
- Examination showed no palpable full thickness defect and a well healed incision.
- MRI obtained demonstrates re-tear at repair site and extension of tendon to bone disruption
- Conservative care attempted for 3 months leading to increasing pain and disability



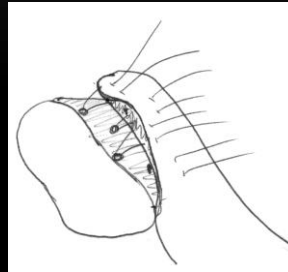
TEAR SITE SURGICAL STRATEGY: FOOTPRINT REPAIR WITH BIOLOGICAL AUGMENT (PATCH & PRP)



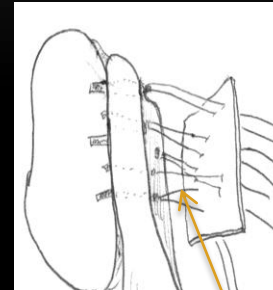
Prepared Site



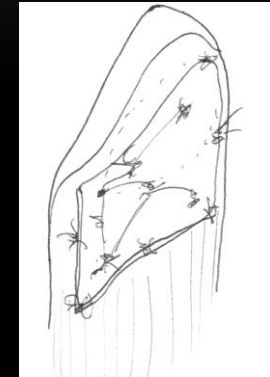
Anchors Placed



Mattress Sutures



Shuttle Graft

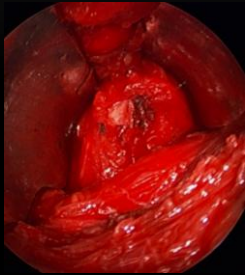


Final Augmented Repair

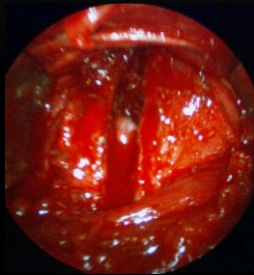
Arthroscope used within dry mini open wound to minimize retraction needs and allow visualization for whole team

PRP Introduced
(ACP Arthrex, Inc)

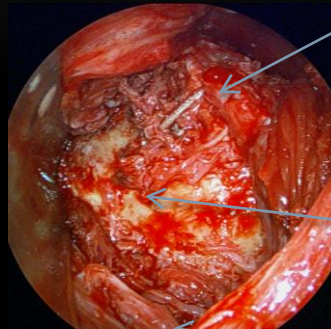
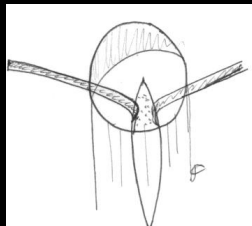
OPERATIVE IMAGES: EXPOSURE OF RETEAR



Exposed PseudoTenon



Linear Division of PseudoTenon: Exposes Re-tear Site Deep Surface

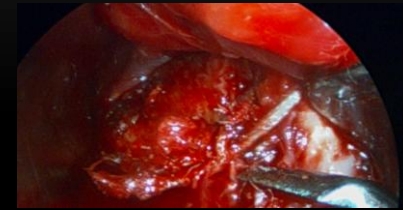


Exposed Ischial Tuberosity: Suture and Knot Retained

Suture Retained (loop and knot intact)

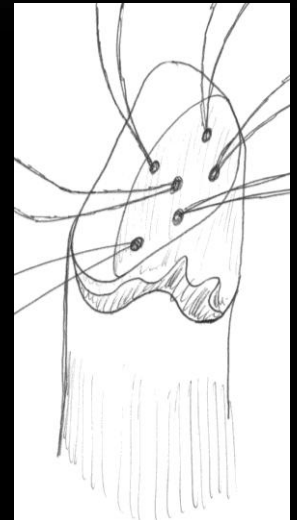
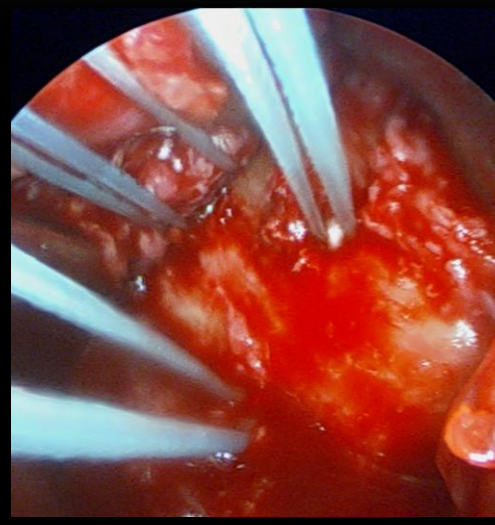
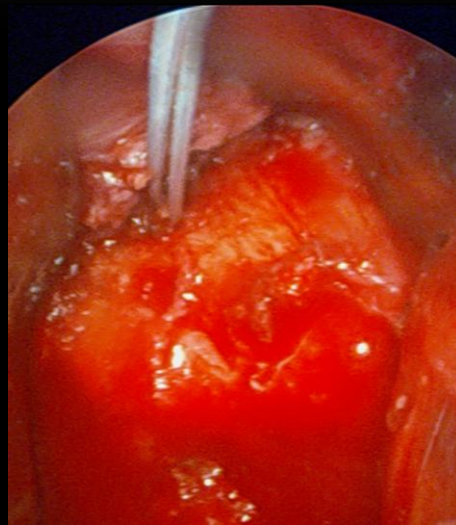
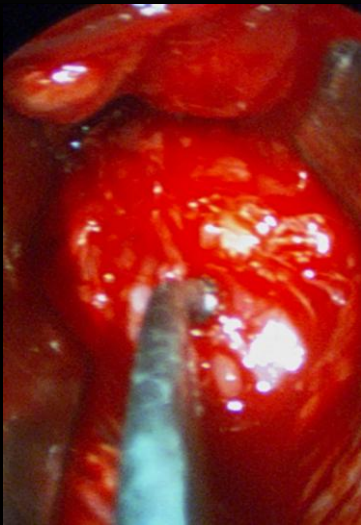
Ischial tuberosity

Mucoid Tissue



Removal of Suture: Arthroscopic Cooter/Graspers

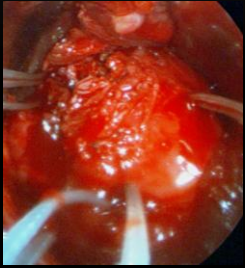
OPERATIVE IMAGES: FOOTPRINT PREPARATION AND ANCHOR PLACEMENT



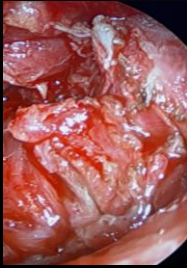
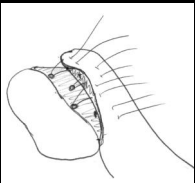
3.0 Bio Absorbable Anchors x 5

OPERATIVE IMAGES:

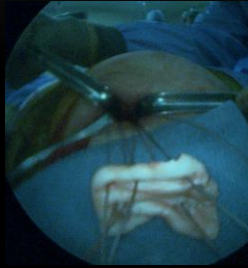
SECURE DEGENERATIVE TENDON & PLACE PATCH AUGMENT (SHUTTLE TECHNIQUE)



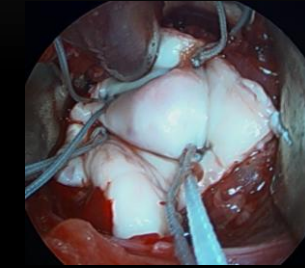
Suture Through Tendon



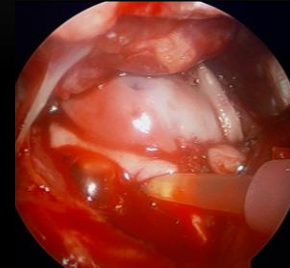
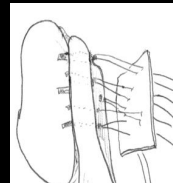
Muroid Tissue Distal To Footprint



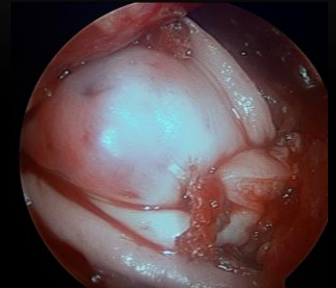Shuttle Graft Using Sutures from Anchor



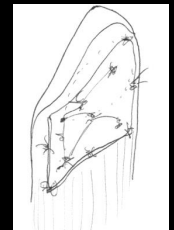
Graft Placed for Trimming



Introduce PRP under graft



Final Repair Site

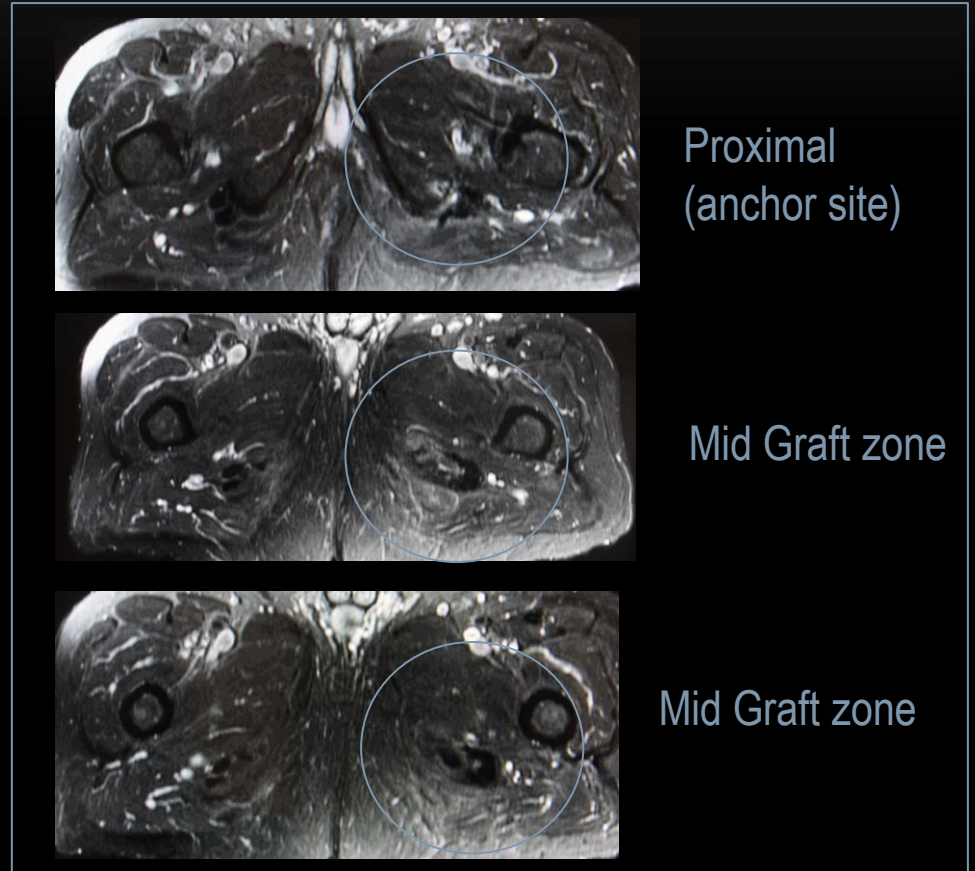
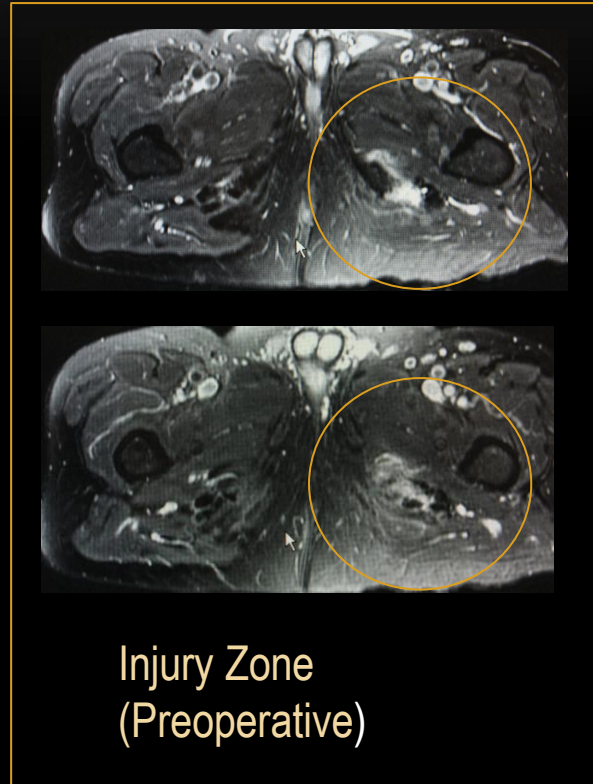

POSTOPERATIVE COURSE:

- Hip orthosis locked at extension for 6 weeks with walker ambulation full weight bearing
- Gluteal and quadriceps isometrics and supine core exercise only during initial period
- Week 6-9: increased hip flexion in orthosis 15 degrees/week with discontinuance of brace after 9 weeks
- Gait based (aquatic and land) rehabilitation week 9-12
- Clear for fitness activity at 12 weeks postoperatively
- Pain free by 2 weeks postoperatively.
- Ambulating without assistance by 7 weeks.
- One year postop patient reports high satisfaction, modified Harris Hip: 100, return to all pre-injury activity.

POSTOPERATIVE OUTCOME: 3 MONTH MRI

AXIAL T2 IMAGES (1.5T WITH SURFACE COIL)



CONCLUSION

- Prior reports of allograft reconstruction of chronic hamstrings tears with tissue deficiency^{5,6}
- Patch augmentation has been used with success in rotator cuff tendon repair in the setting of failed repairs with intact fixation constructs (ie tendon-suture failure)¹
- Biological scaffold for neo-tendon deposition and reinforcing layer for initial repair strength
- PRP has been shown to accelerate hamstrings injury site healing⁸
- No prior reports in English literature for application in proximal hamstrings revision surgery

- This case highlights the strong tendency towards slow healing or failure to heal in elderly active patients with proximal hamstrings injuries.
- Strong consideration should be given to a trial of conservative management due to the increased risk of surgery in this population.
- Upon failure of conservative management, surgical strategy selected should focus on mechanically reestablishing stable contact of tendon origin & augment of native biological healing milieu to optimize chances for success.
- Revision hamstrings surgery can be effective at restoring function and quality of life even in the elderly population.

REFERENCES

- 1 Baker AR, McCarron JA *et al.* Does augmentation with a reinforced fascia patch improve rotator cuff repair outcomes? *Clin Orthop Relat Res.* 2012 Apr 17.
- 2 Birmingham P, Muller M *et al.* Functional outcome after repair of proximal hamstring avulsions. *J Bone Joint Surg Am.* 2011 Oct 5; 93(19):1819-26.
- 3 Cohen S, Bradley J. Acute proximal hamstring rupture. *J Am Acad Orthop Surg.* 2007 Jun; 15(6):350-5.
- 4 Kwan HY, Bae SW *et al.* Early surgical repair of acute complete rupture of the proximal hamstring tendons. *Clin Orthop Surg.* 2011 Sep; 3(3):249-53.
- 5 Murray PJ, Lowe WR. Achilles allograft reconstruction of a chronic complete proximal hamstring rupture. *Knee Surg Sports Traumatol Arthrosc.* 2009 Nov;17(11):1360-3.
- 6 Folsom GJ, Larson CM. Surgical treatment of acute versus chronic complete proximal hamstring ruptures: results of a new allograft technique for chronic reconstructions. *Am J Sports Med.* 2008 Jan; 36(1):104-9
- 7 Randelli P *et al.* Platelet rich plasma in arthroscopic rotator cuff repair: a prospective RCT study, 2-year follow up. *J Shoulder Elbow Surg.* 2011 Jun;20(4):518-28.
- 8 Zhang J, Wang JH. Platelet-rich plasma releasate promotes differentiation of tendon stem cells into active tenocytes. *Am J Sports Med.* 2010 Dec;38(12):2477-86.